

# HEALTH CARE SPANISH

Health Care Spanish Newsletter

November 20, 2015

## Learning on the Go!


The goal of this newsletter is to provide you with enough information to be useful, but not more than can be learned within the busy schedule of a health care worker. You'll find anatomy charts, additional vocabulary, occasional feedback from subscribers, and more! Feel free to read them now and save them for later use such as with a patient or as a study guide for coursework.

## Help Others by Providing Feedback

Part of Health Care Spanish's mission is to create a useful resource for health care workers. However, there is only so much that can be done without feedback from you. Email questions or suggestions to [healthcarespanish@yahoo.com](mailto:healthcarespanish@yahoo.com)

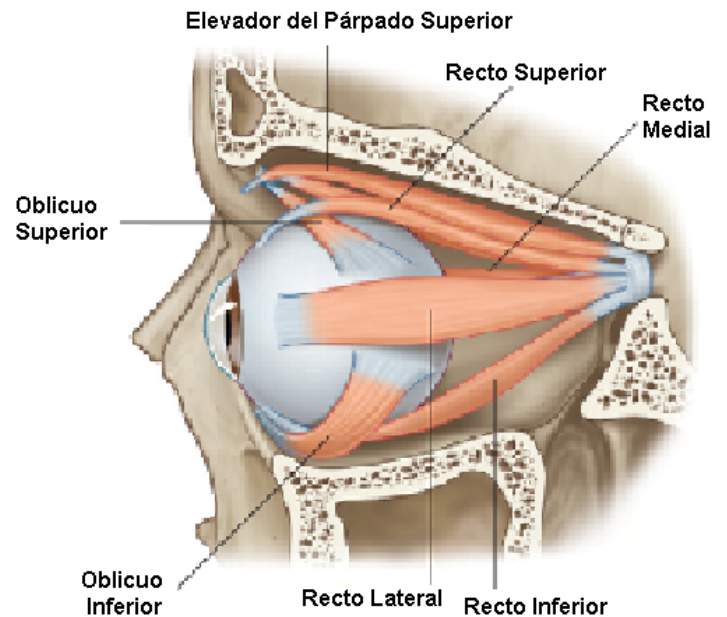
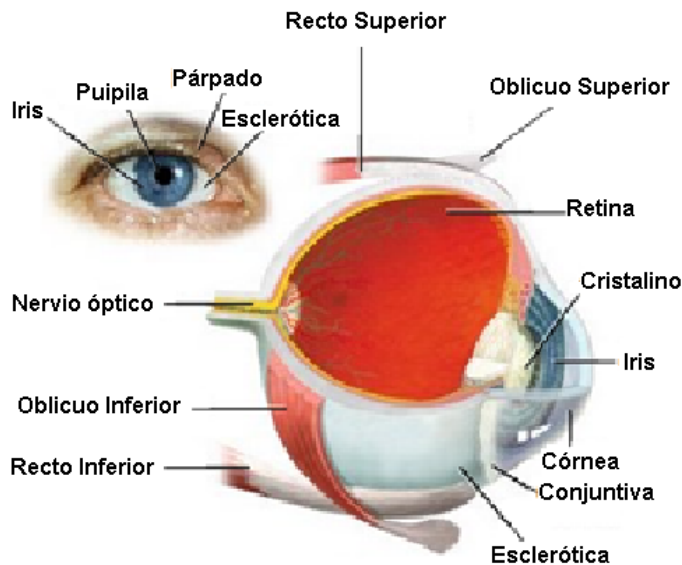
## Spread the Word

Do you know other health care workers or students who need to pick up a little Español? If you find our endeavor useful, we would be grateful if you share it with others.



## In This Issue

- **Anatomy Chart:**  
The Eye
- **Ocular conditions:**  
Strabismus



**Anatomy of the Eye and Extraocular muscles**

**ENGLISH**

**ESPAÑOL**

- Iris**
- Pupil**
- Eyelid**
- Sclera**
- Optic Nerve**
- Lens**

- Iris**
- Pupila**
- Párpado**
- Esclerótica**
- Nervio Óptico**
- Cristalino**

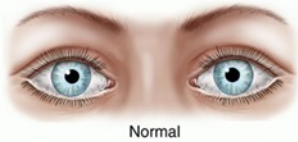- Superior Rectus Muscle:**  
It elevates the eye, and helps with intorsion and adduction.
- Inferior Rectus Muscle:**  
It depresses, and helps extort (rotate laterally) and adduct the eye.
- Medial Rectus Muscle:**  
In charge of adduction of the eye.
- Lateral Rectus Muscle:**  
In charge of abduction of the eye.
- Superior Oblique Muscle:**  
Abducts, depresses and internally rotates the eye.

- Músculo Recto Superior:**  
Eleva y ayuda a aducir y rotar internamente el ojo.
- Músculo Recto Inferior:**  
Lo descinde, aduce y toma parte en la rotación externa del ojo.
- Músculo Recto Medial o Interno:**  
Se encarga de aducir el ojo.
- Músculo Recto Lateral o Externo:**  
Se encarga de abducir el ojo.
- Músculo Oblicuo Superior:**  
Abduce, descinde y rota medialmente el ojo.

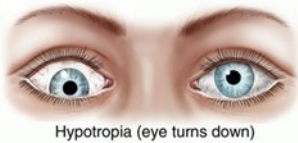- Inferior Oblique Muscle:**  
In charge of extorsion, elevation and abduction of the eye.
- Levator Palpebrae Superioris:**  
Elevates the superior (upper) eyelid.

- Músculo Oblicuo Inferior:**  
Se encarga de abducir, elevar y rotar externamente el ojo.
- Músculo Elevador del Párpado Superior:**  
Eleva el párpado superior

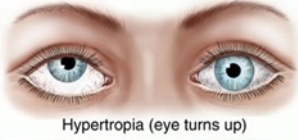## Strabismus



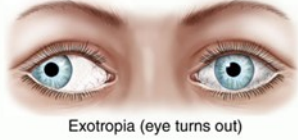Normal



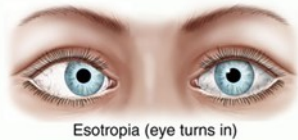Hypotropia (eye turns down)



Hypertropia (eye turns up)



Exotropia (eye turns out)



Esotropia (eye turns in)

**Strabismus** or **heterotropia** is a condition that prevents a person from directing both eyes simultaneously towards the same fixation point. The eyes do not properly align with each other. Strabismus typically involves a lack of coordination between the extraocular muscles.

**Hypotropia:** One eye is turned down.

**Hypertropia:** One eye is turned up.

**Exotropia or Divergent Strabismus:**  
One eye is fixated laterally.

**Esotropia or Convergent Strabismus:**  
One eye is fixated internally.

**Estrabismo o heteroforia** es una condición la cual impide que una persona pueda dirigir ambos ojos simultáneamente hacia un mismo punto de fijación. Los ojos no se alinean correctamente entre sí. El estrabismo suele implicar una falta de coordinación entre los músculos extraoculares.

**Hipotropía o Estrabismo Vertical:**  
Un ojo está desviado hacia abajo.

**Hipertropía o Estrabismo Vertical:**  
Un ojo está desviado hacia arriba.

**Exotropía, exoforia o estrabismo divergente:**  
Un ojo está desviado lateralmente.

**Esotropía, endotropia o estrabismo convergente:**  
Un ojo está desviado medialmente.

## Contact Us

healthcarespanish@yahoo.com

Visit us on the web at [www.healthcarespanish.com](http://www.healthcarespanish.com)

## Contribute

We always welcome input from our readers. If there's a particular anatomy chart or topic you think is important, let's work together to share it with the healthcare community.