

HEALTH CARE SPANISH

Health Care Spanish Newsletter

February 12, 2016

By: Evelin Maza Guia

Learning on the Go!


The goal of this newsletter is to provide you with enough information to be useful, but not more than can be learned within the busy schedule of a health care worker. You'll find anatomy charts, additional vocabulary, occasional feedback from subscribers, and more! Feel free to read them now and save them for later use such as with a patient or as a study guide for coursework.

Help Others by Providing Feedback

Part of Health Care Spanish's mission is to create a useful resource for health care workers. However, there is only so much that can be done without feedback from you. Email questions or suggestions to healthcarespanish@yahoo.com

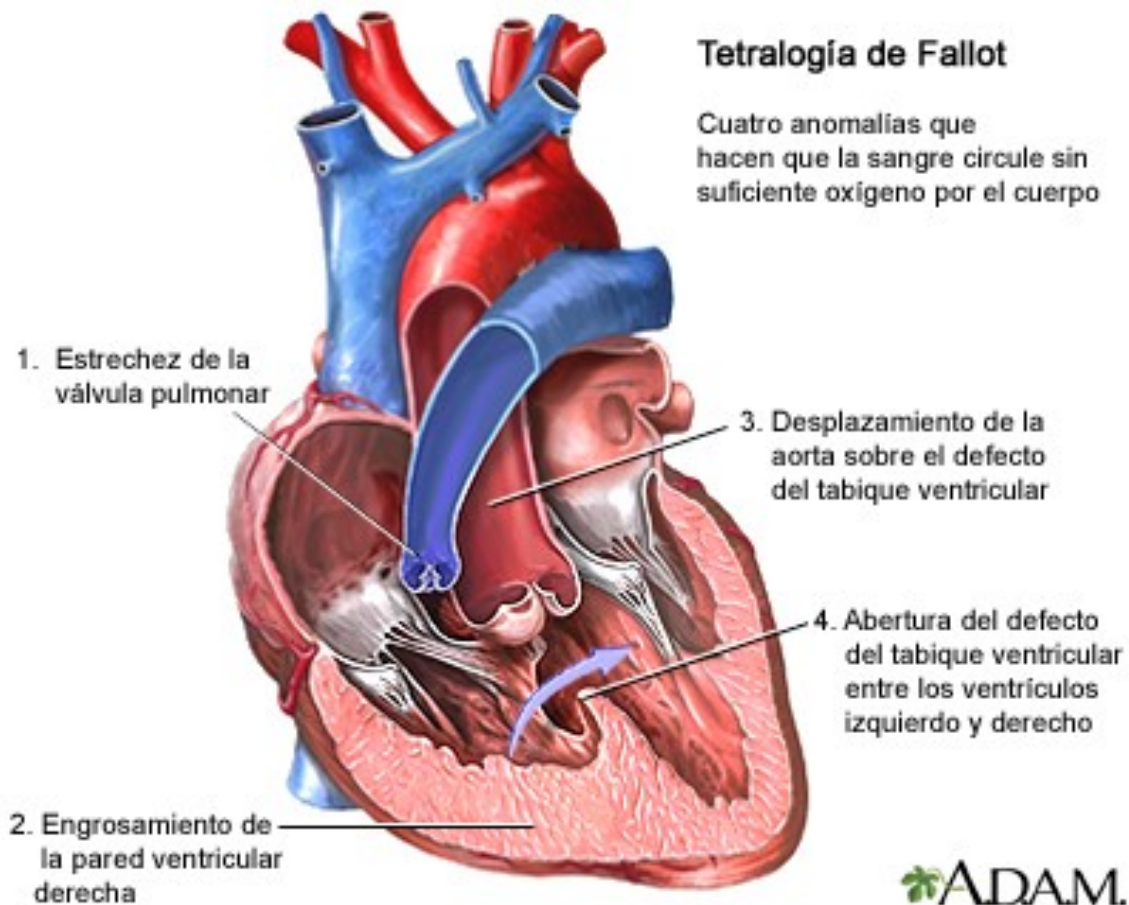
Spread the Word

Do you know other health care workers or students who need to pick up a little Español? If you find our endeavor useful, we would be grateful if you share it with others.



In This Issue

- **Anatomy chart:**
Tetralogy of Fallot



Tetralogía de Fallot

Cuatro anomalías que hacen que la sangre circule sin suficiente oxígeno por el cuerpo

1. Estrechez de la válvula pulmonar

3. Desplazamiento de la aorta sobre el defecto del tabique ventricular

4. Abertura del defecto del tabique ventricular entre los ventriculos izquierdo y derecho

2. Engrosamiento de la pared ventricular derecha

ADAM

Tetralogy of Fallot - Tetralogía de Fallot

Four abnormalities that make the blood circulate throughout the body without enough oxygen

Cuatro anomalías que hacen que la sangre circule sin suficiente oxígeno por el cuerpo

Narrowing of the pulmonary valve, the medical term for this pathology is **Pulmonary Infundibular Stenosis**

Estrechez de la válvula pulmonar, el término médico para esta patología es **Estenosis pulmonar Infundibular**

Thickening of the right ventricular wall, the medical term for this condition is **Right Ventricular hypertrophy**.

Engrosamiento de la pared ventricular derecha, el término médico para esta patología es **Hipertrofia Ventricular Derecha**.

Displacement of the aorta over the ventricular septal defect, the medical term for this condition is **Overriding aorta**.

Desplazamiento de la aorta sobre el defecto del tabique ventricular, el término médico para esta patología es Dextraposisión de la aorta o **Aorta cabalgante**.

Opening in the ventricular septum between the left and right ventricles, the medical term for this condition is **Ventricular Septal Defect**.

Abertura del defecto del tabique ventricular entre los ventrículos izquierdo y derecho, el término médico para esta patología es **Comunicación interventricular**.

Tetralogy of Fallot

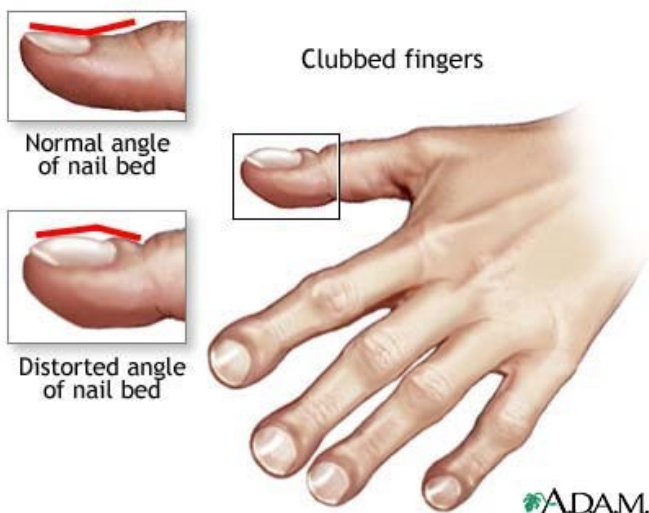Tetralogy of Fallot is a congenital heart defect which usually involves four anatomical abnormalities of the heart. It is the most common cause of **blue baby syndrome**. It results in low oxygenation of blood due to the mixing of oxygenated and deoxygenated blood in the left ventricle via the **ventricular septal defect**, and preferential flow of the mixed blood through the **overriding aorta** because of the obstruction of the **pulmonary stenosis**. This is known as a **right-to-left shunt**.

This condition is characterized by noticeable **cyanosis**, fatigue, a heart murmur, delayed growth and physical development, dyspnea on exertion, and **finger clubbing**. It is common to see these children frequently **squatting**, this is a mechanism to alleviate the hipoxigenación that affects them, due to the increase in systemic vascular resistance.

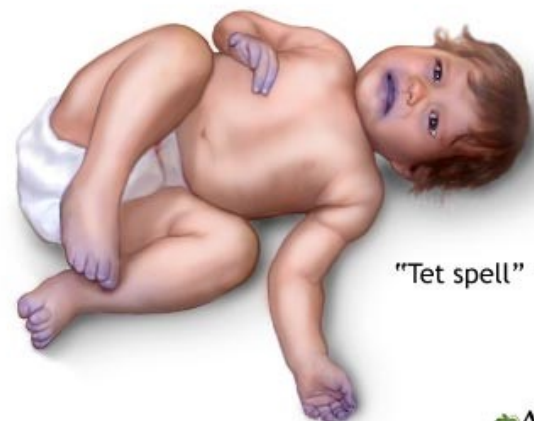Tetralogía de Fallot

La **Tetralogía de Fallot** es un defecto cardíaco congénito que generalmente implica cuatro anomalías anatómicas del corazón. Es la causa más común del **síndrome del bebé azul**. Es el resultado de baja oxigenación de la sangre debido a la mezcla de sangre oxigenada y desoxigenada en el ventrículo izquierdo a través de la **comunicación interventricular**, y el flujo preferencial de la sangre mixta a través de la **aorta cabalgante** debido a la obstrucción de la **estenosis pulmonar**. Esto se conoce como un **cortocircuito de-recta-izquierda**.

Esta patología es caracterizada por una marcada **cianosis**, fatigabilidad, soplos cardíacos, retraso en el crecimiento y el desarrollo físico, disnea de esfuerzo y **dedos en palillo de tambor**. Es común ver a estos niños **acucillarse** frecuentemente, esto es un mecanismo para aliviar la hipoxigenación que los afecta, dado por el aumento de las resistencias vasculares sistémicas.



Children with Tetralogy of Fallot exhibit bluish skin during episodes of crying or feeding.



Contact Us

healthcarespanish@yahoo.com

Visit us on the web at www.healthcarespanish.com

Contribute

We always welcome input from our readers. If there's a particular anatomy chart or topic you think is important, let's work together to share it with the healthcare community.